

## Stereotactic radiation treatment for recurrent nonbenign meningiomas

CARLOS A. MATTOZO, M.D.,<sup>1</sup> ANTONIO A. F. DE SALLES, M.D., PH.D.,<sup>1</sup>  
IVAN A. KLEMENT, M.D.,<sup>2</sup> ALESSANDRA GORGULHO, M.D.,<sup>1</sup> DAVID MCARTHUR, PH.D.,<sup>1</sup>  
JUDITH M. FORD, M.D., PH.D.,<sup>3</sup> NZHDE AGAZARYAN, PH.D.,<sup>3</sup> DANIEL F. KELLY, M.D.,<sup>1</sup>  
AND MICHAEL T. SELCH, M.D.<sup>3</sup>

<sup>1</sup>*Division of Neurosurgery and Departments of* <sup>2</sup>*Pathology and* <sup>3</sup>*Radiation Oncology, University of California at Los Angeles School of Medicine, Los Angeles, California*

**Object.** The authors analyzed the results of stereotactic radiosurgery (SRS) and stereotactic radiotherapy (SRT) for the treatment of recurrent meningiomas that were described at initial resection as showing aggressive, atypical, or malignant features (nonbenign).

**Methods.** Twenty-five patients who underwent SRS and/or SRT for nonbenign meningiomas between December 1992 and August 2004 were included. Thirteen of these patients underwent treatment for multiple primary or recurrent lesions. In all, 52 tumors were treated. All histological sections were reviewed and reclassified according to World Health Organization (WHO) 2000 guidelines as benign (Grade I), atypical (Grade II), or anaplastic (Grade III) meningiomas. The median follow-up period was 42 months.

Seventeen (68%) of the cases were reclassified as follows: WHO Grade I (five cases), Grade II (11 cases), and Grade III (one case). Malignant progression occurred in eight cases (32%) during the follow-up period; these cases were considered as a separate group. The 3-year progression-free survival (PFS) rates for the Grades I, II, and III, and malignant progression groups were 100, 83, 0, and 11%, respectively ( $p < 0.001$ ). In the Grade II group, the 3-year PFS rates for patients treated with SRS and SRT were 100 and 33%, respectively ( $p = 0.1$ ). After initial treatment, 22 new tumors required treatment using SRS or SRT; 17 (77%) of them occurred inside the original resection cavity. Symptomatic edema developed in one patient (4%).

**Conclusions.** Stereotactic radiation treatment provided effective local control of “aggressive” Grade I and Grade II meningiomas, whereas Grade III lesions were associated with poor outcome. The outcome of cases in the malignant progression group was intermediate between that of the Grade II and Grade III groups, with the lesions showing a tendency toward malignancy.

**KEY WORDS** • atypical meningioma • brain tumor • meningioma • malignant meningioma • radiosurgery • tumor classification

**A**TYPICAL and malignant meningiomas are characterized by successive recurrences and aggressive behavior even after complete resection. Their reported incidence among all meningiomas varies, ranging from 4.7 to 6.2% for atypical tumors and from 1.0 to 1.7% for malignant tumors.<sup>10,22,31</sup> Classification of meningiomas has been revised substantially over the last 20 years, with the aim of defining clear criteria for each meningioma variant. The most recent (2000) revision of the WHO meningioma

classification system has been well accepted in the literature and provides reasonably good prognostic correlation.<sup>10, 25,47</sup> Borderline cases exist in all grading schemes. Recurrence and high proliferation rates have been reported in otherwise histologically benign meningiomas.<sup>10,21</sup> An increase in tumor grade (malignant progression) may be noted with successive recurrences of benign or atypical meningiomas. This aspect is not extensively discussed in the literature, but authors of some case series have reported incidence rates ranging from 1.6 to 2% of meningiomas.<sup>22,31,41</sup>

Adjuvant EBRT has been shown to decrease the incidence of tumor recurrence in aggressive meningiomas and improve patient survival rates after subtotal resection.<sup>18,34</sup> Although the effectiveness of SRS and SRT is well recognized for benign meningiomas,<sup>3,7,11,15,27,33,42,45,46</sup> few authors have reported on case series in which patients with atypical

*Abbreviations used in this paper:* EBRT = external-beam radiation therapy; GKS = Gamma Knife surgery; MR = magnetic resonance; PFS = progression-free survival; SRS = stereotactic radiosurgery; SRT = stereotactic radiotherapy; WHO = World Health Organization.

## Stereotactic radiation for recurrent nonbenign meningiomas

and malignant meningiomas were treated with either of these modalities.<sup>9,15,16,19,33,36,45</sup>

In this retrospective study we assessed the results of SRS and SRT in a selected group of patients with recurrent meningiomas not considered benign at initial resection. The data were analyzed after a histological reassessment of the tumors according to the WHO 2000 classification system.

### Clinical Material and Methods

#### Patient Population

The radiosurgery database of the University of California at Los Angeles was retrospectively reviewed. Between December 1992 and August 2004, 395 patients underwent SRS or SRT for treatment of meningiomas. We selected a group of 31 patients who had a history of meningioma resection and recurrence before stereotactic radiation treatment. The majority of tumors were originally classified as atypical or malignant. Tumors described with less defined terms, such as “meningioma with cytological atypia,” “focally aggressive,” or “atypical/malignant features,” were also included. Three patients were excluded because of inadequate follow up. The microscopic slides or blocks from the remaining cases were collected for review, including those from patients who underwent surgery at another facility. Three other patients were excluded for the following reasons: no slide available (one patient), suboptimal specimen (one patient), and diagnosis of a melanoma (one patient).

The histological sections from tumors resected in the 25 remaining patients were analyzed without reference to the previous diagnosis or outcome and were reclassified according to WHO 2000 criteria as benign (Grade I), atypical (Grade II), or anaplastic (Grade III) meningiomas.<sup>30</sup> In cases involving patients who underwent multiple surgeries, we performed a careful analysis of all microscopic slides searching for evidence of malignant progression during the follow-up period. The clinical records were closely examined to identify treatment plan details and complications. Only patients who were followed up for at least 2 years or who were found to have evidence of progression on neuroimages obtained earlier than 2 years after the initial tumor resection were included in this study.

The patient characteristics are summarized in Table 1. Fourteen women and 11 men were included in the study. Their mean age at the time of their first stereotactic radiation treatment was 53 years (range 27–79 years). In the majority of the cases (17 of 25), treatment was indicated on the basis of postsurgical follow-up imaging examinations. Eight patients presented for evaluation as a result of primary complaints as follows: headaches (two patients), cognitive dysfunction (two patients), sixth cranial nerve palsy (two patients), seizure (one patient), and sensory/motor deficit (one patient). All patients in the study group had previously undergone resections (median one resection, range one–three resections). Two patients had undergone EBRT and one patient had undergone proton-beam radiation therapy before undergoing stereotactic radiation treatment in our institution. Two other patients had radiation-induced meningiomas due to previously treated leukemia and nasopharyngeal carcinoma. Three patients received chemotherapy during the follow-up period as part of a clinical trial.

#### Stereotactic Radiation Treatment

The stereotactic radiation treatment technique used in the management of meningiomas at our institution has been described elsewhere.<sup>7,42,46</sup> For the SRS treatments, a BRW (Radionics) or a BrainLAB (BrainLAB AG) stereotactic frame was placed after administration of a local anesthetic. A custom-fitted thermoplastic mask (U-PLAST, BrainLAB AG) was used for immobilization during the SRT procedures.

The tumors were localized using previously acquired 3-mm-slice MR images, which were fused with the computed tomography scans obtained on the treatment day. Three-dimensional treatment plans were generated using commercially available software (BrainLAB).

The radiation was delivered using a Clinac 18 linear accelerator (Varian, Inc.) in five patients treated during the period from 1990 to 1996. Two patients were treated with a dedicated Varian 600 SR linear accelerator (Varian, Inc.) between 1996 and 1998. The Novalis (BrainLAB AG) dedicated system with miniature multileaf collimator capability has been used since 1997 in our institution, and that unit was used to treat 18 patients in this series.

During the follow-up period, 13 patients (52%) underwent treatment for multiple tumors due to the development of new tumors (nine patients), the presence of multiple tumors at presentation (two patients), or both (two patients). A total of 52 tumors were treated in 25 patients. Tumor locations were as follows: convexity (22 tumors), skull base (17 tumors), and parasagittal region (13 tumors). In all, 40 treatment sessions were performed. Thirty-eight tumors were treated in 26 sessions of SRS, and the remaining 14 tumors were treated with SRT. The median treatment volumes were 2.2 cm<sup>3</sup> (range 0.11–65.2 cm<sup>3</sup>) for SRS and 21.3 cm<sup>3</sup> (range 1.3–57.1 cm<sup>3</sup>) for SRT. The peripheral doses ranged from 12 to 18 Gy (median 15.5 Gy) for SRS and 25 to 54 Gy (median 49.3 Gy) for SRT, delivered in 25 to 28 daily fractions (Table 2). One patient received five fractions of 5 Gy for each of two lesions.

#### Follow-Up Imaging

Follow-up imaging consisted of Gd-enhanced MR imaging examinations performed within 3 months of the procedure and then every 6 months thereafter or sooner if indicated. After the second postoperative year, MR imaging studies were performed annually. The median duration of clinical and imaging follow up was 42 months (range 3–119 months). The MR images were reviewed to determine success or failure of local control and identify any radiation-induced changes. Treatment was considered to have failed when an increase in lesion size was observed in any follow-up image.

#### Statistical Analysis

The PFS rate was determined on the basis of the length of time from stereotactic radiation treatment to the appearance of evidence of local recurrence. Survival was measured as the time from the end of a patient's first radiation treatment to the date of his or her death. The Kaplan–Meier method was used to plot PFS for each histological grade and radiation modality (SRS or SRT). Analyses were conducted using the survival library of R statistical software version 2.1.1 (2005; <http://www.r-project.org>).

TABLE 1  
Characteristics of 25 patients\*

Variable	No. (%)
median follow up (mos)	42
age (yrs)	
mean	53
range	27–79
sex	
M	11 (44)
F	14 (56)
prior radiation treatment	
EBRT	2 (8)
proton-beam radiation therapy	1 (4)
indication for treatment of recurrence	
imaging follow up	17 (68)
headaches	2 (8)
cognitive disfunction	2 (8)
CN VI palsy	2 (8)
seizure	1 (4)
sensory/motor deficit	1 (4)

\* Values represent the number of patients unless otherwise indicated. Abbreviation: CN VI = sixth cranial nerve.

## Results

### Histological Analysis

The histological analysis of lesions from patients who underwent multiple surgeries in this series revealed that eight patients (32%) had malignant progression during the follow-up period (Table 3). Four patients had initially benign tumors that evolved to atypical (in two cases) or malignant (in two cases). Three additional patients had documented malignant progression following the diagnosis of atypical meningioma. In one patient the histological characteristics of recurrences progressed from benign to atypical and from atypical to malignant. Overall, 18 tumors were treated in the patients who underwent multiple surgeries. Grouping these tumors according to the grade established at the time of stereotactic radiation treatment yields the following distribution: Grade I, nine lesions; Grade II, four lesions; and Grade III, five lesions. The rates of local control of these lesions at 2-year follow up were: Grade I, 33%; Grade II, 25%; and Grade III, 20%. Since we could not provide a plausible biological rationale for this response to treatment, we decided to group all lesions in which malignant progression occurred as a separate category. Therefore, the patients in this study were ultimately categorized as follows: patients with Grade I tumors, five (20%); patients with Grade II lesions, 11 (44%); patient with a Grade III tumor, 1 (4%); and patients with lesions that showed malignant progression, eight (32%). Additionally, the individual lesions were distributed as follows: Grade I, five lesions; Grade II, 24 lesions; Grade III, five lesions; and malignant progression, 18 lesions (Table 4).

### Tumor Control

**Grade I Meningiomas.** In all five patients in the Grade I group, harboring one lesion each, local control was achieved, with no other lesions developing after treatment with SRS (three patients) or SRT (two patients) (Table 4). The 3-year PFS was 100% for patients with tumors of this grade. The histopathological features of these tumors are summarized in Table 5.

TABLE 2  
Treatment characteristics for 52 tumors

Variable	Value
location (no. of tumors [%])	
convexity	22 (42)
skull base	17 (33)
parasagittal region	13 (25)
treatment modality (no. of tumors [%])	
SRS	38 (73)
SRT	14 (27)
SRS treatment vol (cm <sup>3</sup> )	
median	2.2
range	0.11–65.2
SRS peripheral dose (Gy)	
median	15.5
range	12–18
SRT treatment vol (cm <sup>3</sup> )	
median	21.3
range	1.3–57.1
SRT peripheral dose (Gy)	
median	49.3
range	25–54

**Grade II Meningiomas.** Among the 11 patients with Grade II meningiomas, five (45%) underwent additional stereotactic radiation treatment for nine new lesions arising inside (eight lesions) or outside (one lesion) the original resection cavity and outside the original radiation field (Fig. 1). Of the 24 lesions treated, four (17%) recurred within the field. Treatment failure was observed in two of 19 lesions treated using SRS and in two of five lesions treated using SRT. The 3-year PFS rates for patients with SRS- and SRT-treated Grade II lesions were 100 and 33%, respectively (Table 4). The combined 3-year PFS rate for the two treatment modalities was 83%.

**Grade III Meningiomas.** One patient with Grade III lesions treated with SRS without previous EBRT had poor tumor control. Eight months after SRS, he presented with a local recurrence of a convexity lesion and underwent SRS treatment for three new lesions outside the original surgical cavity and one lesion involving the previously irradiated tumor. Treatment failure was evident in all of these lesions 4 to 7 months after treatment. Thus, the 1-year PFS was 0% for Grade III meningiomas (Table 4).

**Meningiomas Characterized by Malignant Progression.** Among the eight patients presenting with meningiomas with malignant progression, five (63%) underwent treatment for nine new lesions arising outside (one lesion) or

TABLE 3  
Tumor grades according to WHO 2000 reclassification

Group	No. of Cases (%)
Grade I	5 (20)
Grade II	11 (44)
Grade III	1 (4)
malignant progression	8 (32)
Grade I to Grade II	2
Grade I to Grade III	2
Grade II to Grade III	3
Grade I to Grade II & Grade II to Grade III	1

## Stereotactic radiation for recurrent nonbenign meningiomas

TABLE 4

*Tumor control and PFS according to WHO 2000 reclassification*

Variable	Value
Grade I	
no. of lesions	5
SRS failure	0/3
SRT failure	0/2
3-yr PFS for SRS	100%
3-yr PFS for SRT	100%
Grade II	
no. of lesions	24
SRS failure	2/19
SRT failure	2/5
3-yr PFS for SRS	100%
3-yr PFS for SRT	33%
Grade III	
no. of lesions	5
SRS failure	5/5
1-yr PFS for SRS	0%
malignant progression	
no. of lesions	18
SRS failure	11/11
SRT failure	5/7
3-yr PFS for SRS	9%
3-yr PFS for SRT	14%

inside (eight lesions) the original resection cavity. Three of these lesions involved a tumor previously irradiated by SRS (two lesions) or SRT (one lesion). Of the 18 lesions treated, 16 (89%) recurred. Treatment failure was observed in all 11 lesions treated with SRS, whereas treatment failure was observed in only five of the seven lesions treated with SRT (Fig. 2). Additionally, local treatment failure was observed in all three lesions retreated for growth inside the field originally treated by means of SRS. The 3-year PFS rates for patients with SRS- and SRT-treated lesions were estimated at 9 and 14%, respectively (Table 4). The 1- and 3-year PFS rates for the two treatment modalities combined were 61 and 11%, respectively.

In summary, 11 of the 25 the patients developed 22 new tumors, 17 inside and five outside the original surgical resection cavity, after initial stereotactic radiation treatment. The PFS curves for the four groups—the three WHO 2000 grades and the cases involving lesions that showed evidence of malignant progression—considering SRS and SRT combined, are shown in Fig. 3. The difference between these curves was statistically significant ( $p < 0.001$ ).

### Clinical Response

Twenty patients (80%) were clinically stable after treatment. Two patients (8%) had symptomatic improvement of a sixth cranial nerve palsy (one patient) and seizures (one patient). Symptom progression was observed in three patients (12%); in all three cases it was associated with tumor progression as seen in imaging studies. One patient who underwent SRT for treatment of a Grade II cavernous sinus and Meckel's cave meningioma experienced an increase in facial numbness 14 months after treatment. One patient who underwent SRT for treatment of what was initially a Grade I lesion, a sphenoid wing meningioma that extended into the orbit and cavernous sinus, had loss of vision as well as ophthalmoplegia in the left eye associated with tumor progression 19 months after treatment. Histological examination was performed after a new resection, and the lesion was found to have the characteristics of a Grade II meningioma. Another patient, who underwent SRS for treatment of a recurrent tentorial Grade III meningioma, experienced vision worsening due to perilesional edema and local mass effect caused by tumor progression in the area of the occipital pole.

In total, six patients had died by the last follow up. In three cases, the cause of death was related to tumor progression, including one case in which the patient developed an intraparenchymal hematoma. In two other patients the specific cause of death was not determined, although tumor progression was documented at the last follow-up examination. One patient died of Fournier gangrene. The 3-year survival rates for patients in the Grade I, Grade II, and malignant progression groups were 100, 100, and 57%, respectively. The patient treated for a Grade III meningioma died 17 months after treatment.

### Complications of Treatment

One patient who had undergone whole-brain radiation therapy as a child because of leukemia underwent multiple resections and stereotactic radiation treatment for a radiation-induced meningioma. Malignant transformation was also documented in this case (Fig. 2). The patient was a 29-year-old woman who developed radiation-induced edema and experienced an increase in epileptic activity after undergoing SRT for treatment of a large meningioma. Although the patient experienced clinical improvement after steroid therapy, the lesion was resected due to an increase in mass effect. Another patient developed asymptomatic radiation-induced edema after undergoing SRT for a mar-

TABLE 5

*Histopathological features of the five meningiomas classified as Grade I after reclassification\**

Specimen No.	Initial Histopathological Finding	Findings on Review				
		Abnormal Cellularity	Nuclear Pleomorphism	Nucleoli	Other Pathological Findings	Mitotic Activity
1	cytological atypia	NP	pronounced	prominent	NP	inconspicuous
2	focally high proliferation rate	increased	NP	small	Ki 67: 15–20%	inconspicuous
3	atypical features	NP	pronounced	small	NP	inconspicuous
4	atypical features	focally increased	NP	small	bone invasion	focally increased
5	focally aggressive features	focally increased	NP	prominent	NP	inconspicuous

\* NP = not present.



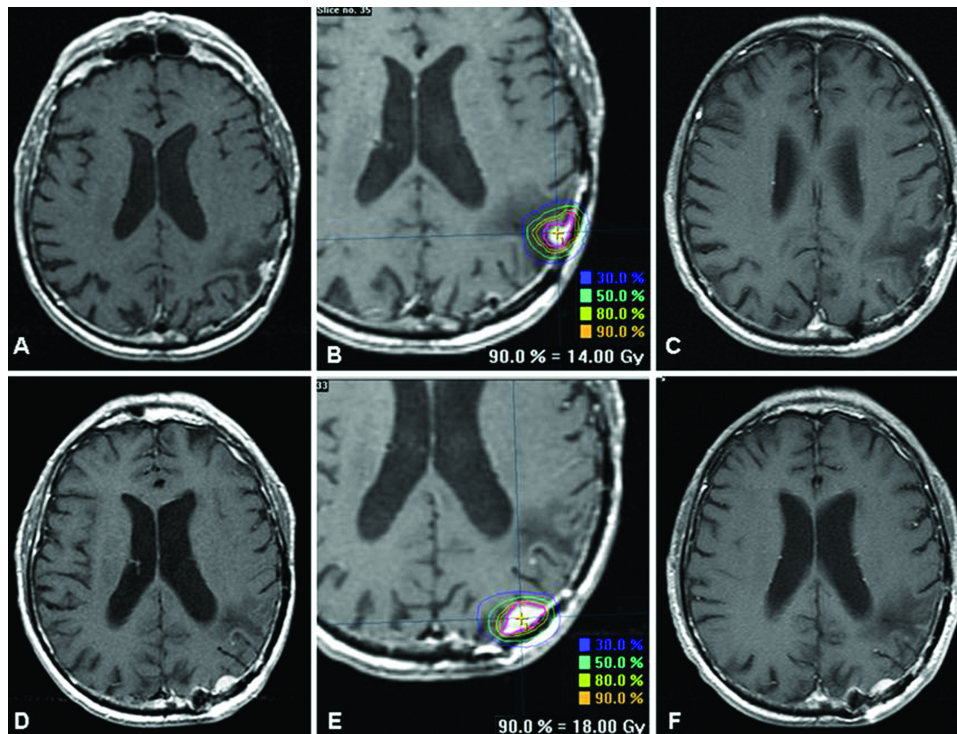


FIG. 1. Axial MR images obtained in a 78-year-old man who had undergone surgery for a Grade II meningioma 5 years earlier and developed a recurrent lesion (A and B), which was treated using SRS. This lesion was under control 18 months after treatment (C), although 6 months after the first SRS session another lesion was found to have developed inside the original tumor resection cavity (D). A second session of SRS was required for this new lesion (E), which was under control after 1 year of follow up (F).

ginal recurrence of a meningioma that had been treated previously by means of SRS and that had progressed from Grade II to Grade III.

### Discussion

The unpredictable behavior of a subset of meningiomas was recognized by Horsley in 1883, Krause in 1910, and Cushing in 1938.<sup>44</sup> Although atypical meningioma was recognized by the WHO classification in 1993,<sup>29</sup> the delineation between the three grades was considered by many to be ill defined.<sup>14,17,26,35,37–39</sup> Several previously adopted classification schemes failed to predict behavior of borderline cases.<sup>6,22,31,32</sup> The present data suggest that, except for those tumors that show characteristics of malignant progression at initial histological evaluation, the WHO 2000 classification system helps to stratify recurrent meningiomas managed with stereotactic radiation treatment into groups that have prognostic significance.

#### Malignant Progression Cases

Malignant progression in meningiomas is associated with aggressive behavior of the tumors, and its mechanism is still unclear. The pattern of genetic alterations in these lesions has been shown to include changes in the short arm of chromosome 1 and in the long arms of chromosomes 10 and 14.<sup>5,28,43</sup> The incidence rate of 32% in the present study is slightly higher than the rates (range 18–27%) that have

been reported in previously published series of cases of atypical and malignant meningiomas.<sup>16,20,37,49</sup> The higher incidence in our study could be related to the selection criteria we used, including only recurrent tumors, as well as the high degree of complexity of the cases referred to our clinic.

Given the retrospective method of the present report, doubt existed about which histological grade should be considered for the cases demonstrating malignant progression during follow up. The pathology report represents an assessment of the tumor at the time of a given resection and, considering that malignant transformation is a dynamic process, it is impossible to estimate what histological characteristics the tumor had at the exact time of treatment.

The data from the present study demonstrate that patients who experienced malignant progression had clinically very aggressive tumors, even when they were considered to be Grade I meningiomas based on their histological characteristics. The finding of 67% local treatment failure at the 2-year follow up in this group of meningiomas after stereotactic radiation treatment suggests that local failure of stereotactic radiation treatment was a predictor of propensity for malignant progression in this series. Furthermore, considering tumors demonstrating malignant progression as a separate group, regardless of histological grade, allowed a distinct, statistically significant clinical correlation for the remaining groups of tumors (WHO Grades I, II, and III). Unfortunately, we could not identify histological features to differentiate this group from others, and including

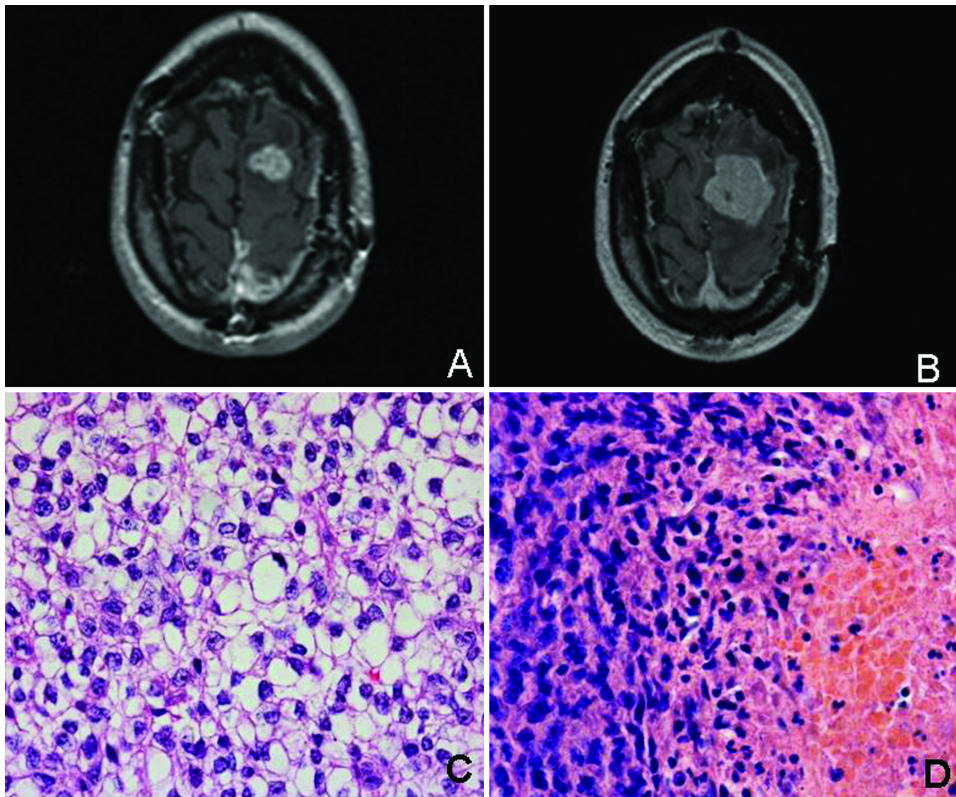


FIG. 2. A and B: Pretreatment (A) and 9-month posttreatment (B) axial MR images obtained in a 29-year-old woman treated using SRS for a Grade II meningioma. The image obtained 9 months after treatment shows tumor recurrence. C and D: Photomicrographs of sections showing malignant progression from Grade II (C) to Grade III (D). The section in panel C is from a specimen obtained at resection of the original tumor, prior to SRS, showing characteristics of a Grade II meningioma. The section in panel D is from a specimen obtained at resection of the recurrence after failure of radiation therapy, showing characteristics of a Grade III meningioma. H & E, original magnifications  $\times 20$  (C) and  $\times 10$  (D).

this subgroup of tumors in the Grade I, II, and III groups would have biased our series. Interestingly, the combination of the relatively high 3-year survival rate of 57% that was observed for patients in the malignant progression group and the low local control rate of 11% at 3 years indicates an intermediate behavior between Grades II and III for these tumors that demonstrated dedifferentiation on histopathological examination.

Al-Mefty et al.<sup>2</sup> recently used fluorescence in situ hybridization to study four cases of meningioma with malignant progression. They found that a complex karyotype involving deletion of 1p and 14q was present “ab initio” in lower-grade tumors that subsequently demonstrated malignant progression, apparently contradicting the stepwise clonal evolution model for dedifferentiated tumors. This finding seems to support our suggestion of classifying those meningiomas as a separate group having its own characteristics. A detailed description of our cases in which malignant progression was present will be reported in a separate study.

#### *The Role of Radiation Treatment in the Management of Nonbenign Meningiomas*

**External-Beam Radiation Therapy.** Surgery is the first-line therapy for nonbenign meningiomas.<sup>12,37,38</sup> Although limited by small numbers of patients, the results of retrospective studies have suggested that EBRT might improve outcome

in patients with atypical or malignant meningiomas.<sup>12,13,20,34</sup> Nevertheless, the application of different radiation schemes and the variety of classification criteria adopted in the definition of histological malignancy make analysis of the literature difficult. The 5-year local control rates reported by authors of studies on atypical and malignant meningiomas range from 38 to 56% and from 44 to 52%, respectively.<sup>13,20,24</sup> Dziuk et al.<sup>12</sup> reported that adjuvant radiation therapy following initial resection of malignant meningiomas increased the 5-year PFS rates from 15 to 80%.

Traditionally, EBRT has been recommended for atypical meningiomas after microsurgery<sup>24</sup> or only for residual tumors.<sup>18</sup> For malignant meningiomas, patients are referred to radiation therapy regardless of the extent of resection.<sup>18,24,48</sup> Some authors recommend starting the radiation treatment immediately after surgery.<sup>12,34</sup>

Higher doses of radiation were reported to achieve better local control rates for atypical and malignant meningiomas,<sup>20,34</sup> although Katz et al.<sup>24</sup> recently reported a lack of benefit from accelerated hyperfractionated radiotherapy with 60 Gy plus a radiosurgery boost. This treatment scheme was unacceptably toxic and yielded no improvement in local control.

**Stereotactic Radiation Treatment.** Benign meningiomas have been effectively controlled with SRS<sup>11,15,27,45,46</sup> or SRT.<sup>3,7,33,42,46</sup> Five-year local control rates greater than 90%

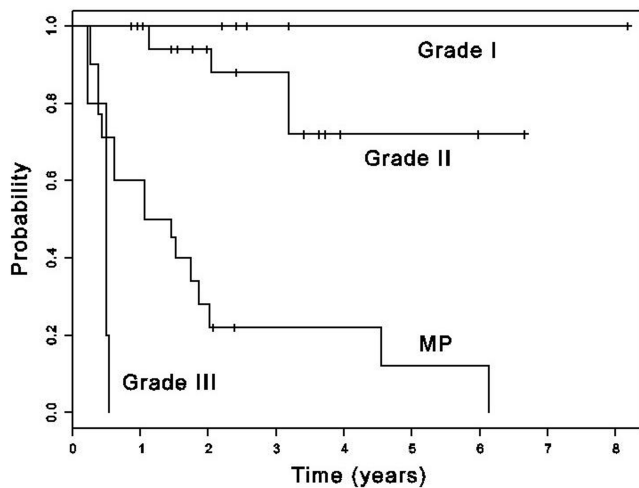


FIG. 3. Kaplan–Meier curves showing PFS according to WHO 2000 criteria for Grades I, II, and III meningiomas and meningiomas with malignant progression (MP) in cases treated with SRS and SRT ( $p < 0.001$ ).

have been reported for both techniques.<sup>27,33,45</sup> In the present study, we obtained a 3-year PFS rate of 100% for the Grade I tumors. One should note that this group was made up of meningiomas with some aggressive features, which did not, however, fulfill the criteria for WHO Grade II tumors. Some of their histomorphological features have been described as suspicious in the literature: prominent nucleoli,<sup>6,35,38,41</sup> nuclear pleomorphism,<sup>5,6,21,26,31,37,41</sup> increased cellularity,<sup>10,21,23,29,31,37,38,41</sup> and high proliferation rate.<sup>1,10,17,26,35</sup>

Few reports that focus on the application of SRS and SRT for treatment of Grades II and III meningiomas provide a clear description of the histological classification system applied. Previously published studies and their various classification systems are summarized in Table 6.

Harris et al.<sup>16</sup> obtained 5-year local control rates of 83 and 72% for atypical and malignant meningiomas, respectively, using GKS. Surprisingly, the 5-year survival rate was the same (59%) for both histological types. These results may

be due in part to the classification system the authors applied. The great majority of the tumors in their case series were classified with brain invasion considered as a criterion for atypical meningioma.<sup>38</sup> Furthermore, malignant progression could play a role in local control rate. We have demonstrated in the current study that better survival rates can be expected in cases with malignant progression, so the fact that progression from lower grades was present in 27% of the cases in the series reported by Harris et al. could explain the high survival rate that they observed in their patients with malignant meningiomas. Similarly, in our previously published series about stereotactic radiation treatment of benign and atypical meningiomas without histological review, a low local control rate of only 38% was found for atypical tumors.<sup>46</sup> Therefore, it seems reasonable to identify and exclude these cases when performing analysis of local control and survival for Grades I, II, and III meningiomas.

Huffmann et al.<sup>19</sup> used the WHO 2000 classification system in their study of Grade II meningiomas treated by SRS. They reported survival and local control rates of 93 and 95%, respectively, at a median follow up of 35 months and observed that their smallest dose of radiation (15 Gy) was related to local relapse. In the present case series, we obtained local control in all eight Grade II meningiomas treated with doses lower than 15 Gy (range 12–14 Gy). The only two Grade II tumors in which there was local treatment failure were treated with a 16-Gy dose (the mean dose applied for tumors of Grade II histological characteristics). Considering the 3-year PFS rate of 100% that we obtained for Grade II lesions, it seems that higher doses of radiation are not required for treatment of atypical meningiomas.

Ojemann et al.<sup>36</sup> reported on 22 patients treated by SRS for malignant meningioma after EBRT. They used the WHO 1993 classification or Jääskeläinen<sup>22</sup> classification and obtained a 5-year survival rate of 40% and a PFS rate of 26%. The high rate of radiation necrosis observed in their series (23%) is probably related to the previous EBRT received by all patients. Conversely, only 12% of our patients had previously received EBRT or proton-beam radiation therapy, which could explain our smaller rate of side effects. Moreover, we had a 1-year PFS rate of 0% and a relatively short survival period in our single case of malig-

TABLE 6

Reported rates of tumor control and patient survival in cases of Grades II and III meningiomas treated using SRS or SRT\*

Authors & Year	Treatment	Classification System	Histological Findings	% Cases w/ Tumor Control	% Patients Surviving
Hakim et al., 1998	SRS, LINAC	WHO 1993	atypical malignant	67† 81†	22 at 4 yrs 83 at 4 yrs
Ojemann et al., 2000	SRS, GKS	WHO 1993 or Jääskeläinen et al., 1986	malignant	26 at 5 yrs	40 at 5 yrs
Debus et al., 2001	SRT, LINAC	WHO‡	atypical	78 at 3 yrs	—
Stafford et al., 2001	SRS, GKS	WHO‡	atypical malignant	0 at 5 yrs 68 at 5 yrs	0 at 5 yrs 76 at 5 yrs
Harris et al., 2003	SRS, GKS	Perry et al., 1999	atypical malignant	72 at 5 yrs 83 at 5 yrs	59 at 5 yrs 59 at 5 yrs
Huffmann et al., 2005	SRS, GKS	WHO 2000	atypical	95 at 3 yrs	93 at 3 yrs
Milker-Zabel et al., 2005	SRT, LINAC	WHO‡	atypical	89 at 5 yrs	—

\* LINAC = linear accelerator; — = data not provided.

† Time frame not specified.

‡ Edition not specified.



nant meningioma. Similar results were obtained by Stafford et al.<sup>45</sup> using GKS.

The low control rate achieved with SRT in Grade II meningiomas in the present study is in disagreement with the 5-year PFS rate of 89% reported by the University of Heidelberg group, although they do not specify which WHO version they used.<sup>9,33</sup>

The main challenge in the treatment of nonbenign meningiomas is their capability to develop consecutive multiple local recurrences, usually at the borders or in the vicinity of the first operation.<sup>4,8,40,44</sup> Thus, the application of focused stereotactically guided radiation for each new nodule arising in this way seems to be of limited efficacy. This pattern is demonstrated in the present study, in which 55% of the patients with nonbenign meningiomas developed new lesions after the initial radiation treatment for relapse, the majority (77%) of them inside the original tumor bed. Huffmann et al.<sup>19</sup> reported that 40% of patients treated by SRS for atypical meningiomas developed marginally or distant recurrent tumors during follow up.

On the basis of the results of the present study, we suggest that at relapse of previously resected atypical or malignant meningiomas the whole cavity should be treated with stereotactic radiation treatment to reduce the incidence of further tumor bed relapses, with a radiosurgery boost to the recurrent nodule if desired. By extrapolation it may be appropriate to treat the tumor cavity right away after initial surgery to reduce the risk of any relapse. In cases of extensive tumors, EBRT may be necessary. After tumor bed irradiation, any recurrent nodules should be approached with SRS.

The reliability of any classification system has a particular impact on the study of Grade II meningiomas, considering that these lesions could be erroneously classified as Grade I or III by the inclusion or withdrawal of histological criteria. Given the variety of classifications adopted historically in the literature and the relatively small number of series in which the WHO 2000 classification has been applied, it is difficult to compare the data in the literature. We believe that the behavior and treatment response of meningiomas will only be understood when an accurate classification system is universally adopted.

### Conclusions

Both SRS and SRT were associated with acceptable local control and survival rates in "aggressive" Grade I and Grade II meningiomas in our study, whereas our patient with Grade III lesions had poor local control and survival.

Once a nonbenign meningioma has recurred, further recurrence, mainly inside the original tumor resection cavity, is relatively common. This finding suggests that at recurrence the whole cavity should receive radiation therapy.

The behavior of lesions demonstrating malignant progression was intermediate between that of Grade II and Grade III lesions; the success of local control of these lesions tended to be more like that of malignant lesions than that of atypical lesions, but the survival rate for patients with lesions demonstrating malignant potential was relatively high. When we considered those lesions as a separate grade, the WHO 2000 classification provided good clinical correlation in Grades I, II, and III meningiomas.

Failure of stereotactic radiation treatment in Grade I meningiomas was a predictor of malignant transformation in this case series.

### Disclosure

Dr. De Salles is a member of the BrainLAB speakers bureau. Dr. Gorgulho is supported in part by a fellowship from BrainLAB.

### References

1. Abramovich CM, Prayson RA: MIB-1 labeling indices in benign, aggressive, and malignant meningiomas: a study of 90 tumors. **Hum Pathol** 29:1420-1427, 1998
2. Al-Mefty O, Kadri PA, Pravdenkova S, Sawyer JR, Stangeby C, Husain M: Malignant progression in meningioma: documentation of a series and analysis of cytogenetic findings. **J Neurosurg** 101:210-218, 2004
3. Andrews DW, Faroozan R, Yang BP, Hudes RS, Werner-Wasik M, Kim SM, et al: Fractionated stereotactic radiotherapy for the treatment of optic nerve sheath meningiomas: preliminary observations to observation with or without prior surgery. **Neurosurgery** 51:890-904, 2002
4. Borovich B, Doron Y, Braun J, Guilburd JN, Zaaroor M, Goldsher D, et al: Recurrence of intracranial meningiomas: the role played by regional multicentricity. Part 2: Clinical and radiological aspects. **J Neurosurg** 65:168-171, 1986
5. Cerda-Nicolas M, Lopez-Gines C, Perez-Bacete M, Barcia-Salorio JL, Lombart-Bosch A: Histopathological and cytogenetic findings in benign, atypical and anaplastic human meningiomas: a study of 60 tumors. **Clin Neuropathol** 19:259-267, 2000
6. de la Monte SM, Flickinger J, Linggood RM: Histopathologic features predicting recurrence of meningiomas following subtotal resection. **Am J Surg Pathol** 10:836-843, 1986
7. De Salles AA, Frighetto L, Grande CV, Solberg TD, Cabatan-Awang C, Selch MT, et al: Radiosurgery and stereotactic radiation therapy of skull base meningiomas: proposal of a grading system. **Stereotact Funct Neurosurg** 76:218-229, 2001
8. de Vries J, Wakhloo AK: Repeated multifocal recurrence of grade I, grade II, and grade III meningiomas: regional multicentricity (primary new growth) or metastases? **Surg Neurol** 41:299-305, 1994
9. Debus J, Wuendrich M, Pirzkall A, Hoess A, Schlegel W, Zuna I, et al: High efficacy of fractionated stereotactic radiotherapy of large base-of-skull meningiomas: long-term results. **J Clin Oncol** 19:3547-3553, 2001
10. Devaprasath A, Chacko G: Diagnostic validity of the Ki-67 labeling index using the MIB-1 monoclonal antibody in the grading of meningiomas. **Neurol India** 51:336-340, 2003
11. DiBiase SJ, Kwok Y, Yovino S, Arena C, Naqvi S, Temple R, et al: Factors predicting local tumor control after gamma knife stereotactic radiosurgery for benign intracranial meningiomas. **Int J Radiat Oncol Biol Phys** 60:1515-1519, 2004
12. Dziuk TW, Woo S, Butler EB, Thornby J, Grossman R, Dennis WS, et al: Malignant meningioma: an indication for initial aggressive surgery and adjuvant radiotherapy. **J Neurooncol** 37:177-188, 1998
13. Goldsmith BJ, Wara WM, Wilson CB, Larson DA: Postoperative irradiation for subtotally resected meningiomas. A retrospective analysis of 140 patients treated from 1967 to 1990. **J Neurosurg** 80:195-201, 1994
14. Goyal LK, Suh JH, Mohan DS, Prayson RA, Lee J, Barnett GH: Local control and overall survival in atypical meningioma: a retrospective study. **Int J Radiat Oncol Biol Phys** 46:57-61, 2000
15. Hakim R, Alexander E III, Loeffler JS, Shrieve DC, Wen P, Fallon MP, et al: Results of linear accelerator-based radiosurgery for intracranial meningiomas. **Neurosurgery** 42:446-454, 1998



16. Harris AE, Lee JY, Omalu B, Flickinger JC, Kondziolka D, Lunsford LD: The effect of radiosurgery during management of aggressive meningiomas. **Surg Neurol** **60**:298–305, 2003
17. Ho DM, Hsu CY, Ting LT, Chiang H: Histopathology and MIB-1 labeling index predicted recurrence of meningiomas: a proposal of diagnostic criteria for patients with atypical meningioma. **Cancer** **94**:1538–1547, 2002
18. Hoffmann W, Muhleisen H, Hess CF, Kortmann RD, Schmidt B, Grote EH, et al: Atypical and anaplastic meningiomas—does the new WHO-classification of brain tumors affect the indication for postoperative irradiation? **Acta Neurochir (Wien)** **135**:171–178, 1995
19. Huffmann BC, Reinacher PC, Gilsbach JM: Gamma knife surgery for atypical meningiomas. **J Neurosurg** **102 (Suppl)**:283–286, 2005
20. Hug EB, Devries A, Thornton AF, Munzenrider JE, Pardo FS, Hedley-Whyte ET, et al: Management of atypical and malignant meningiomas: role of high-dose, 3D-conformal radiation therapy. **J Neurooncol** **48**:151–160, 2000
21. Jääskeläinen J, Haltia M, Laasonen E, Wahlstrom T, Valtonen S: The growth rate of intracranial meningiomas and its relation to histology. An analysis of 43 patients. **Surg Neurol** **24**:165–172, 1985
22. Jääskeläinen J, Haltia M, Servo A: Atypical and anaplastic meningiomas: radiology, surgery, radiotherapy, and outcome. **Surg Neurol** **25**:233–242, 1986
23. Jellinger KA, Slowik F: Histological subtypes and prognostic problems in meningiomas. **J Neurol** **208**:279–298, 1975
24. Katz TS, Amdur RJ, Yachnis AT, Mendenhall WM, Morris CG: Pushing the limits of radiotherapy for atypical and malignant meningioma. **Am J Clin Oncol** **28**:70–74, 2005
25. Kleihues P, Louis DN, Scheithauer BW, Rorke LB, Reifenberger G, Burger PC, et al: The WHO classification of tumors of the nervous system. **J Neuropathol Exp Neurol** **61**:215–229, 2002
26. Kolles H, Niedermayer I, Schmitt C, Henn W, Feld R, Steudel WI, et al: Triple approach for diagnosis and grading of meningiomas: histology, morphometry of Ki-67/Feulgen stainings, and cytogenetics. **Acta Neurochir (Wien)** **137**:174–181, 1995
27. Kondziolka D, Levy EI, Niranjan A, Flickinger JC, Lunsford LD: Long-term outcomes after meningioma radiosurgery: physician and patient perspectives. **J Neurosurg** **91**:44–50, 1999
28. Lamszus K, Kluwe L, Matschke J, Meissner H, Laas R, Westphal M: Allelic losses at 1p, 9q, 10q, 14q, and 22q in the progression of aggressive meningiomas and undifferentiated meningeal sarcomas. **Cancer Genet Cytogenet** **110**:103–110, 1999
29. Louis DN, Budka H, von Deimling A: Meningiomas, in Kleihues P, Cavenee WK (eds): **Pathology and Genetics of Tumours of the Nervous System**. Lyon: IARC Press, 1997, pp 35–38
30. Louis DN, Scheithauer BW, Budka H, von Deimling A, Kepes JJ: Meningiomas, in Kleihues P, Cavenee WK (eds): **Pathology and Genetics of Tumours of the Nervous System**. Lyon: IARC Press, 2000, pp 176–189
31. Mahmood A, Caccamo DV, Tomecek FJ, Malik GM: Atypical and malignant meningiomas: a clinicopathological review. **Neurosurgery** **33**:955–963, 1993
32. Maier H, Ofner D, Hittmair A, Kitz K, Budka H: Classic, atypical, and anaplastic meningioma: three histopathological subtypes of clinical relevance. **J Neurosurg** **77**:616–623, 1992
33. Milker-Zabel S, Zabel A, Schulz-Ertner D, Schlegel W, Wannemacher M, Debus J: Fractionated stereotactic radiotherapy in patients with benign or atypical intracranial meningioma: long-term experience and prognostic factors. **Int J Radiat Oncol Biol Phys** **61**:809–816, 2005
34. Milosevic MF, Frost PJ, Laperriere NJ, Wong CS, Simpson WJ: Radiotherapy for atypical or malignant intracranial meningioma. **Int J Radiat Oncol Biol Phys** **34**:817–822, 1996
35. Niedermayer I, Kolles H, Zang KD, Feiden W: Characterization of intermediate type (WHO “atypical”) meningiomas. **Clin Neuropathol** **15**:330–336, 1996
36. Ojemann SG, Sneed PK, Larson DA, Gutin PH, Berger MS, Verhey L, et al: Radiosurgery for malignant meningioma: results in 22 patients. **J Neurosurg** **93 (3 Suppl)**:62–67, 2000
37. Palma L, Celli P, Franco C, Cervoni L, Cantore G: Long-term prognosis for atypical and malignant meningiomas: a study of 71 surgical cases. **Neurosurg Focus** **2(4)**:E3, 1997
38. Perry A, Scheithauer BW, Stafford SL, Lohse CM, Wollan PC: “Malignancy” in meningiomas: a clinicopathologic study of 116 patients, with grading implications. **Cancer** **85**:2046–2056, 1999
39. Perry A, Stafford SL, Scheithauer BW, Suman VJ, Lohse CM: Meningioma grading: an analysis of histologic parameters. **Am J Surg Pathol** **21**:1455–1465, 1997
40. Philippon J, Cornu P: The recurrence of meningiomas, in Al-Mefty O (ed): **Meningiomas**. New York: Raven Press, 1991, pp 87–105
41. Rohringer M, Sutherland GR, Louw DF, Sima AA: Incidence and clinicopathological features of meningioma. **J Neurosurg** **71**:665–672, 1989
42. Selch MT, Ahn E, Laskari A, Lee SP, Agazaryan N, Solberg TD, et al: Stereotactic radiotherapy for treatment of cavernous sinus meningiomas. **Int J Radiat Oncol Biol Phys** **59**:101–111, 2004
43. Simon M, von Deimling A, Larson JJ, Wellenreuther R, Kaskel P, Waha A, et al: Allelic losses on chromosomes 14, 10, and 1 in atypical and malignant meningiomas: a genetic model of meningioma progression. **Cancer Res** **55**:4696–4701, 1995
44. Simpson D: The recurrence of intracranial meningiomas after surgical treatment. **J Neurol Neurosurg Psychiatry** **20**:22–39, 1957
45. Stafford SL, Pollock BE, Foote RL, Link MJ, Gorman DA, Schomberg PJ, et al: Meningioma radiosurgery: tumor control, outcomes, and complications among 190 consecutive patients. **Neurosurgery** **49**:1029–1038, 2001
46. Torres RC, Frighetto L, De Salles AA, Goss B, Medin P, Solberg T, et al: Radiosurgery and stereotactic radiotherapy for intracranial meningiomas. **Neurosurg Focus** **14(5)**:E5, 2003
47. Willis J, Smith C, Ironside JW, Erridge S, Whittle IR, Everington D: The accuracy of meningioma grading: a 10-year retrospective audit. **Neuropathol Appl Neurobiol** **31**:141–149, 2005
48. Wilson CB: Meningiomas: genetics, malignancy, and the role of radiation in induction and treatment. The Richard C. Schneider Lecture. **J Neurosurg** **81**:666–675, 1994
49. Younis GA, Sawaya R, DeMonte F, Hess KR, Albrecht S, Bruner JM: Aggressive meningeal tumors: review of a series. **J Neurosurg** **82**:17–27, 1995

---

Manuscript submitted December 13, 2005.

Accepted September 18, 2006.

Address reprint requests to: Antonio A. F. De Salles, M.D., Ph.D., 200 UCLA Medical Plaza, Suite 504, Los Angeles, California 90095. email: adesalles@mednet.ucla.edu.